

SOME VARIETIES OF PATHOLOGICAL CHANGES IN EXPERIMENTAL INFECTION OF CARPS (*Cyprinus carpio*) WITH *Aeromonas hydrophila*

Deyan STRATEV¹, Stoycho STOEV², Ivan VASHIN¹, Hristo DASKALOV³

¹ Department of Hygiene and Control of Food Products from Animal Origin, Faculty of Veterinary Medicine, Trakia University, Stara Zagora, Bulgaria

² Department of General and clinical pathology, Faculty of Veterinary Medicine, Trakia University, Students campus, Stara Zagora, Bulgaria

³ NDRVMI, Bulgarian Food Safety Agency, Sofia, Bulgaria

Received: 12.04.2015

Accepted: 01.07.2015

Published online: 24.07.2015

Corresponding author:

Stoycho STOEV, Department of General and clinical pathology, Faculty of Veterinary Medicine, Trakia University, Bulgaria

E-mail: stoev@uni-sz.bg

Abstract:

The main clinical and pathomorphological changes in *Aeromonas hydrophila* infection in carp provoked by different field strains of this bacterium were studied. The strongest histopathological damages were seen in the functional epithelium of liver and kidneys, followed by intestine and hearth damages in addition to various haemorrhages in interstitial tissues of visceral organs and some skin haemorrhages on the ventral surface of the body and the anal region. As a whole, pathological damages consisted of degenerative changes as cloudy swelling, granular and/or hyaline droplet degeneration or vacuolation in functional epithelium in the respective internal organs in addition to

some target vascular disturbances, which appeared to be good biomarkers for field assessment of that disease. Pathological damages in internal organs and haemorrhages were stronger in experimental fishes exposed to higher levels of the respective pathogens, especially those isolated from dead anaconda or the referent strain, and less pronounced damages were seen in fishes infected with of *Aeromonas hydrophila* isolated from a silver carp with marked signs of septicaemia.

Keywords: Carp, Infection, Pathology, Pathomorphological changes, *Aeromonas hydrophila*

Introduction

Aeromonas hydrophila is a common inhabitant of aquatic environments and is considered to be one of the usual constituents of the superficial and intestinal flora of cool or cold-water fishes (Lallier and Daigneault, 1984; Dooley et al., 1986), but is not necessarily restricted to fresh water environment and is often isolated from raw and processed products of marine fishes (Thampuran and Surendran, 1995). *Aeromonas hydrophila*, however, behaves frequently as a secondary invader and is responsible for the disease known as motile aeromonad septicemia (Roberts, 1978). Therefore, this bacterium is also known as one of the most important pathogens of freshwater fishes, which is commonly isolated from fish affected by ulcerative disease outbreaks accompanied by severe hemorrhages of the body surface. This disease is also known as red pest for European eel *Anguilla anguilla*, red disease for Japanese eel *A. japonica* (Hoshina, 1962), red disease for carp *Cyprinus carpio* or red sore for largemouth bass *Micropterus salmonides* (Huizinga et al., 1979). Having in mind different kind of fishes fell sick by the same disease, it is not so strange that there are some contradictions in clinical and pathomorphological signs described by some authors in different fish species (Miyazaki and Kubota, 1977; Miyazaki and Jo, 1985; Miyazaki and Kaige, 1985; Azad et al., 2001; Alagappan et al., 2009; Yardimci and Aydin, 2011). This infectious disease is also known to reduce catfish production by nearly 10% every year and is considered to be one of the common diseases accounting for the decrease of fish production (Alagappan et al., 2009). In humans, *Aeromonas hydrophila* infection has been associated with gastroenteritis and localized wound infection, especially in individuals who have an immune deficiency (Nemetz and Shotts, 1993) and therefore is of the primary concern for public health.

Having in mind the mentioned above contradictions in clinical and pathomorphological signs in different fish species as described by some authors and the reduced fish production, which can be provoked by this disease, in addition to significant health problems in humans, our objectives in this study were to clarify whether there are some differences in clinical and pathomorphological findings of this particular disease in carp as provoked by different strains of *Aeromonas hydrophila* and the possible contamination of fish produce with the same pathogen.

Materials and Methods

Experimental strains

Two of the *Aeromonas hydrophila* strains were isolated from the field, whereas the other was a referent strain. One of the field strains was isolated from a silver carp with marked signs of septicemia, whereas the other strain was isolated from a dead anaconda. These strains were provided by the National Reference Lab on Fish, Marine Molluscs and Crustacean Diseases (Sofia, Bulgaria). The reference *A. hydrophila* (ATCC 7965) strain was purchased from the National Bank for Industrial Microorganisms and Cell Cultures (Sofia, Bulgaria). All strains exhibited β -haemolytic activity. The strains were activated 18 hours prior to the experiment by inoculation in soybean casein broth (CASO broth, Merck), incubated at 30 °C for replication to a density of $\sim 10^9$. From initial cultures, a series of 10-fold dilutions were performed in Maximum Recovery Diluent (MRD, Merck) in order to obtain bacterial concentrations of 10^{-8} , 10^{-7} , 10^{-6} and 10^{-5} which were further used for experimental intraperitoneal infection of experimental carps.

Experimental design

An experiment was performed with 2-year-old carps, weighing from 850 to 1200 g and infected with 3 different *Aeromonas hydrophila* strains. The carps were divided in three experimental and one control group of 12 fishes each. Each carp was also marked and injected intraperitoneally with 0.5 mL of the respective bacterial culture dilution as described above. A total three fish were inoculated with each dilution. The injected carps were released into 4 separate tanks containing 800 l water each, where a constant aeration was maintained and a part of the water was also changed each day. The carps were monitored over a period of 10 days for possible changes in their behaviour, mortalities and visible pathological changes. After that period, fish were percussive stunned according to Ordinance N 15/3.02.2006 about minimum requirements for the protection and welfare of experimental animals, and then a sample was obtained from the heart via a sterile needle for bacteriological examination as per Compendium of Methods for the Microbiological Examination of Foods (Palumbo et al., 2001) by means of blood inoculation onto selective medium for *Aeromonas* spp. (GSP agar, Merck). The experimental carps were

killed by destroying of cerebrum before regaining consciousness according to the mentioned above minimum requirements for the protection and welfare of experimental animals. The spleen and kidney were aseptically removed, and inoculations were made using the same selective medium as described above. Gross pathological examination was performed, and specimens for pathomorphological studies were collected from the spleen, kidney, hepatopancreas, intestine and hearth and fixed in 10% neutral buffered formalin. The fixed tissues were processed for paraffin embedding, sectioned at 6 μ m and stained with haematoxylin-eosin.

The study protocol of this experiment was approved by the Trakia University Animal Care Ethic Committee as required.

Results and Discussion

Microbiological investigations revealed that the original *Aeromonas* strains were re-isolated from all investigated samples of the fishes infected with the respective strains. There were no cases of death within the 10-day period of monitoring in the infected fishes from all groups. No significant change in the fish behaviour such as anorexia or the way of swimming was noticed. Only swimming closer to water surface was seen in some fishes from all experimental groups.

Experimental fishes infected with *Aeromonas hydrophila* isolated from anaconda

The external examination of experimental fishes after the 10-day period showed a lot of haemorrhages, particularly on the ventral surface of the body and in the anal region, especially in carps injected with the highest levels of this pathogen.

In the intestine, there were degenerative changes and desquamation of epithelial cells of intestinal mucosa. Partial necrosis and desquamation was also observed in the villi which corresponded to desquamative catarrh in the intestine. The same was accompanied by bacterial invasions in the epithelium, tunica propria or submucosa and was most obvious and pronounced in fishes exposed to higher microbial density via the intraperitoneal infection. A hypersecretion of Goblet cells was also observed.

In the hearth, there was slight intermuscular edema, small hemorrhages and irregular staining of some myofibrils due to their increased aci-

dophily. Some lytic changes, cloudy swelling, slight to moderate granular degeneration or vacuolation were also observed in part of myofibrils (Figure 1).

In the liver, there was moderate to strong granular degeneration or vacuolation of hepatocytes (Figure 2) accompanied with extensive deposition of hemosiderin in hepatocytes or macrophages.

In the kidneys, there was moderate to strong granular and/or hyaline droplet degeneration, necrosis and desquamation of tubular epithelium (Figure 3). Cellular debris and/or hyaline casts were seen in some tubules. Some nuclei of tubular epithelium showed pyknotic changes and there was deposition of hemosiderin in the epithelial cells of tubules and an increased quantity of hemosiderin-laden macrophages in the hematopoietic tissues. Sinusoids of the peritubular hematopoietic tissue were congested and some hemorrhages were also evident in the renal interstitium.

In the spleen, there was an extensive deposition of hematoidin crystals and a lot of hemosiderin-laden macrophages in the pulp.

Experimental fishes infected with *Aeromonas hydrophila* isolated from a silver carp

A few haemorrhages were detected on the ventral surface of the body and in the anal region, especially in carps injected with the highest levels of this pathogen.

In the intestine, the degenerative changes and desquamation of epithelial cells of intestinal mucosa and the partial necrotic changes in the villi were less pronounced in comparison to those described in the carps of previous group (Figure 4). A bacterial invasion in the epithelium, tunica propria or submucosa was also seen, but the same was most obvious only in fishes exposed to higher microbial density of the diluent used for intraperitoneal infection.

In the hearth, there were small hemorrhages and increased acidophily or irregular staining of some myofibrils. Slight intermuscular edema and granular degeneration or vacuolation were also observed in part of myofibrils.

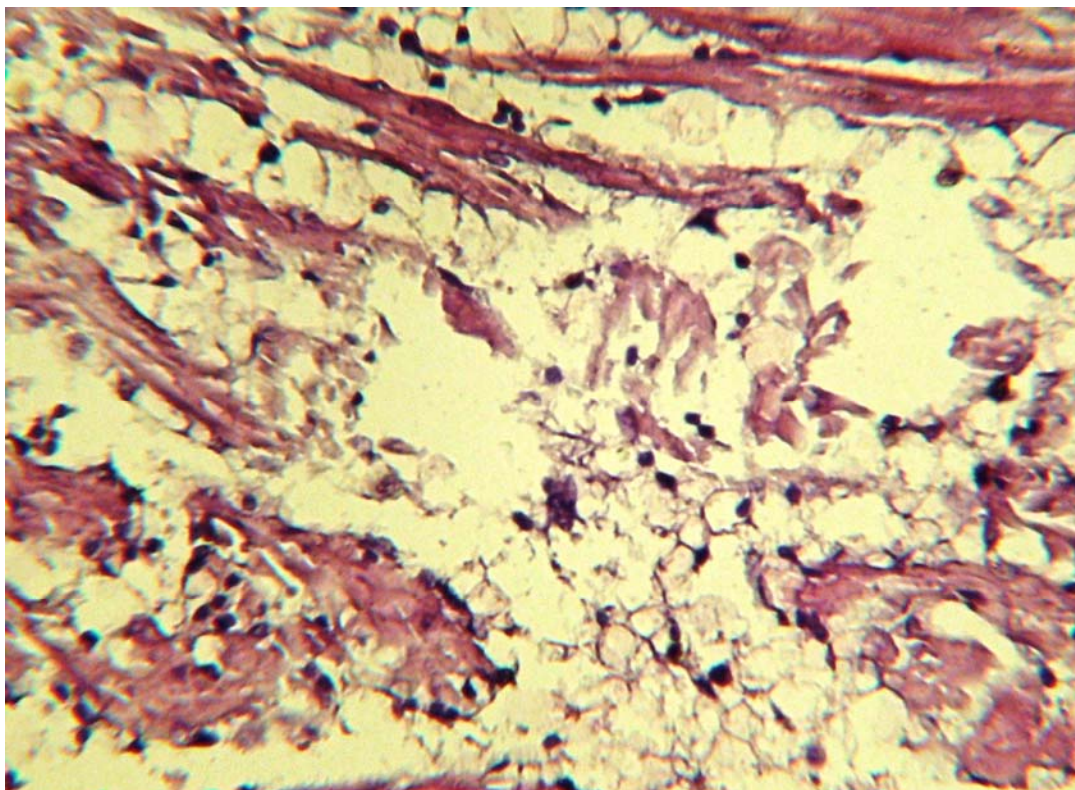


Figure 1. Lytic changes, granular degeneration or vacuolation in some myofibrils. Heart. HE. $\times 260$.

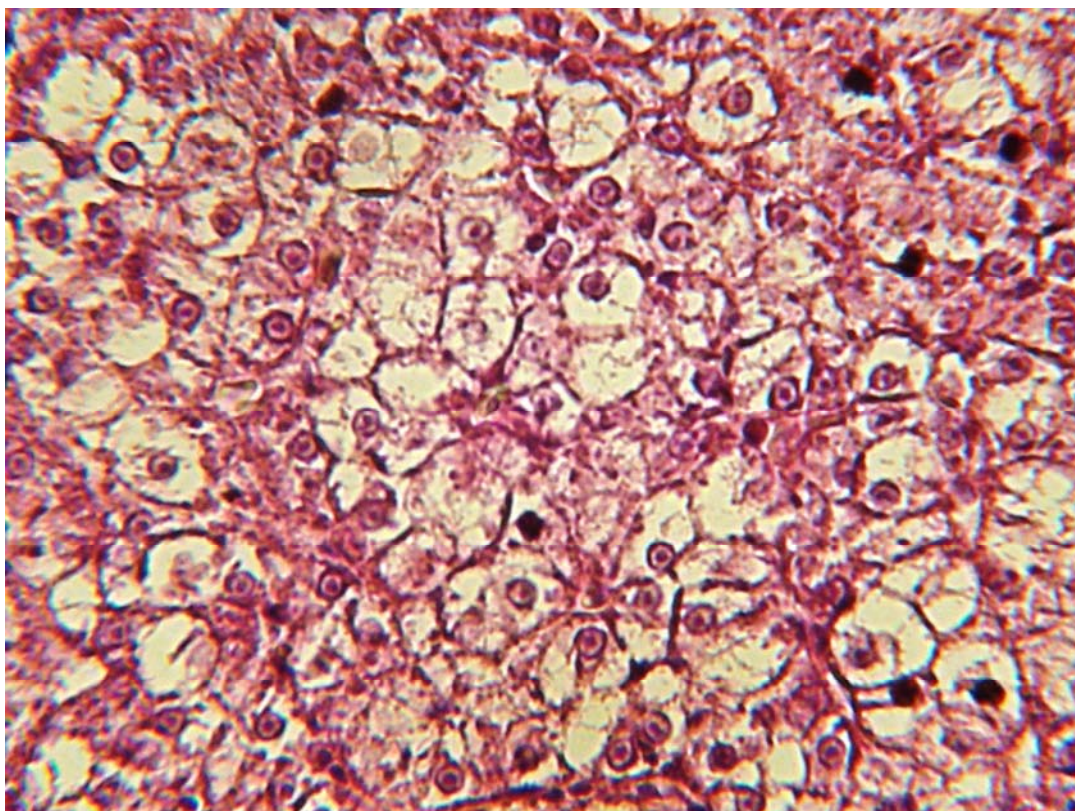


Figure 2. Granular degeneration or vacuolation in hepatocytes. Liver. HE. $\times 260$.

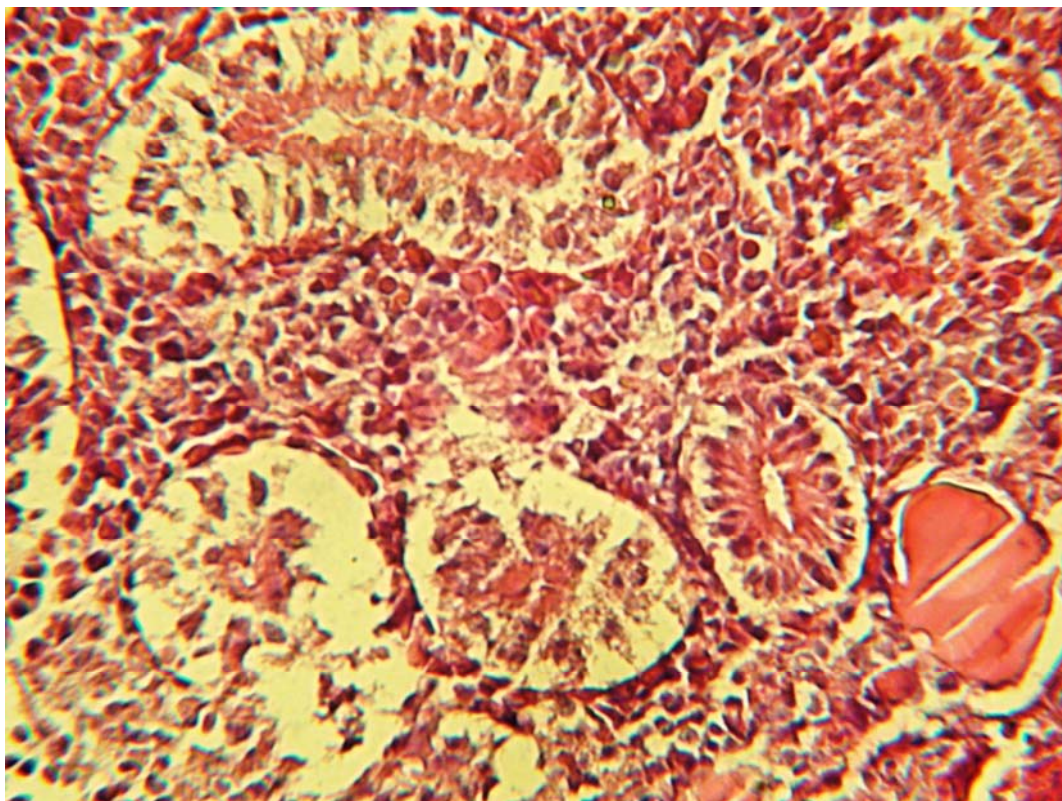


Figure 3. Granular degeneration and desquamation of tubular epithelium and hyaline casts in tubular lumens. Kidney. HE. $\times 260$.

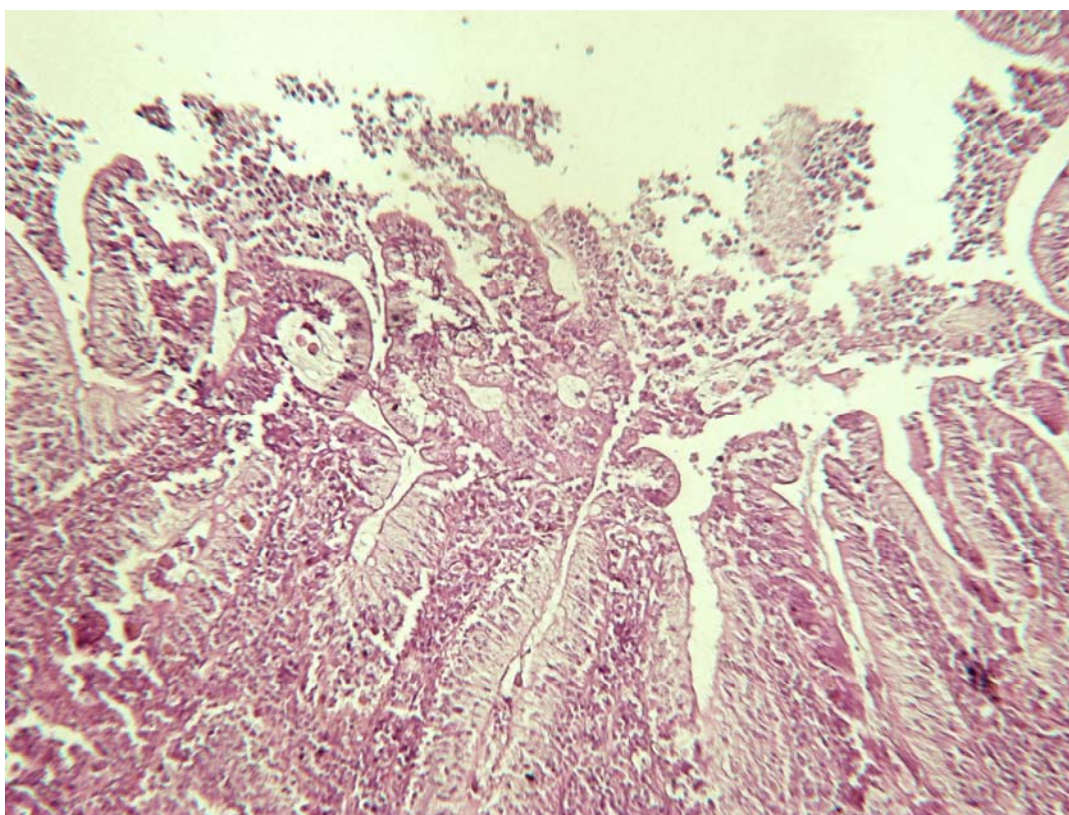


Figure 4. Desquamation of epithelial cells of intestinal mucosa and partial necrotic changes in the villi. Intestine. HE. $\times 100$.

In the liver, there was moderate to strong granular degeneration or vacuolation of hepatocytes. A deposition of hemosiderin in hepatocytes or macrophages was also seen.

In the kidneys, there was moderate granular degeneration and desquamation of tubular epithelium. Some nuclei of tubular epithelium showed pyknotic changes and there was deposition of hemosiderin in the epithelial cells of some tubules (Figure 5). An increased quantity of hemosiderin-laden macrophages in the hematopoietic tissues was seen (Figure 5). Hyaline and/or cellular casts were also observed in the lumens of some tubules (Figure 6).

In the spleen, there was an extensive deposition of hematoidin crystals and a lot of hemosiderin-laden macrophages in the pulp.

Experimental fishes infected with referent species of *Aeromonas hydrophila*

A lot of haemorrhages on the ventral surface of the body and in the anal region were seen, mainly in carps injected with the highest levels of *Aeromonas hydrophila*.

In the intestine, degenerative changes and desquamation of epithelial cells of intestinal mucosa (desquamative catarrh) were seen in all examined fishes. Partial necrosis and desquamation was observed in the intestinal villi. Bacterial invasions in the epithelium, tunica propria or submucosa were seen in some fishes exposed to higher microbial density of diluent. Some necrotic foci with peripheral inflammatory cell infiltration were also seen in the tunica propria or lamina muscularis of intestinal mucosa (Figure 7) probably because of bacterial invasion.

In the hearth, there were small hemorrhages (Figure 8) in addition to lytic changes, slight to moderate granular degeneration or vacuolation (Figure 8) in part of myofibrils.

In the liver, there was slight to moderate granular degeneration or vacuolation of hepatocytes accompanied with deposition of hemosiderin in hepatocytes or macrophages.

In the kidneys, there were slight to moderate degenerative changes and desquamation in the tubular epithelium in addition to some hyaline casts in tubular lumens. There was an increased quantity of hemosiderin-laden macrophages in the hematopoietic tissues. Many hemorrhages

were also seen in the renal interstitium in addition to the fibrin/hyaline thrombi in some vessels.

In the spleen, there was an extensive deposition of hematoidin crystals and a lot of hemosiderin-laden macrophages in the pulp in addition to small fibrin/hyaline thrombi in some vessels.

Control fishes

There were no pathomorphological changes in internal organs and only a slight granular degeneration or karyopyknosis was sometimes seen in a few epithelial cells of kidney tubules and a single hyaline drops in their lumens. A slight granular degeneration was also seen in a few hepatocytes in the liver.

The comparison of pathomorphological findings revealed that the strongest damages were found in the liver and kidneys, followed by the hearth and the intestine and only slight damages were seen in the spleen. As a whole pathological damages consisted of degenerative changes (cloudy swelling, granular and/or hyaline droplet degeneration or vacuolation) in functional epithelium in the respective internal organs in addition to the hyperaemia and haemorrhages in their interstitial tissues.

Pathological damages in internal organs were more pronounced and stronger in experimental fishes exposed to higher levels of the respective pathogens, which was achieved by higher microbial density of diluent injected intraperitoneally (especially at levels 10^9 cfu/cm³). LD₅₀ for *Aeromonas hydrophila* usually range between $0.3 \times 10^{8.66}$ cell/fish in carps (Alsaphar and Al-Faragi, 2012) and $10^{6.22}$ cell/fish in tilapia (Azad et al., 2001) after intramuscular injection up to 6.66×10^{11} cells/ mL in matrinxã *Brycon amazonicus* after intraperitoneal injection of 0.1 mL suspension (Oliveira et al., 2011).

Similar pathological damages and increased mortality in Walking Catfish infected intraperitoneally with *Aeromonas hydrophila* were also reported by Angka (1990), where the pathomorphological changes were more pronounced in catfishes infected with higher levels of bacteria (10^7 cfu/mL) compared to those infected with lower levels of the same bacteria. According to the same author the catfishes injected intraperitoneally with such low levels of bacteria as 0.1 mL of a suspension containing 10^3 cfu/mL of *Aeromonas hydrophila* did not cause significant disease in the catfish.

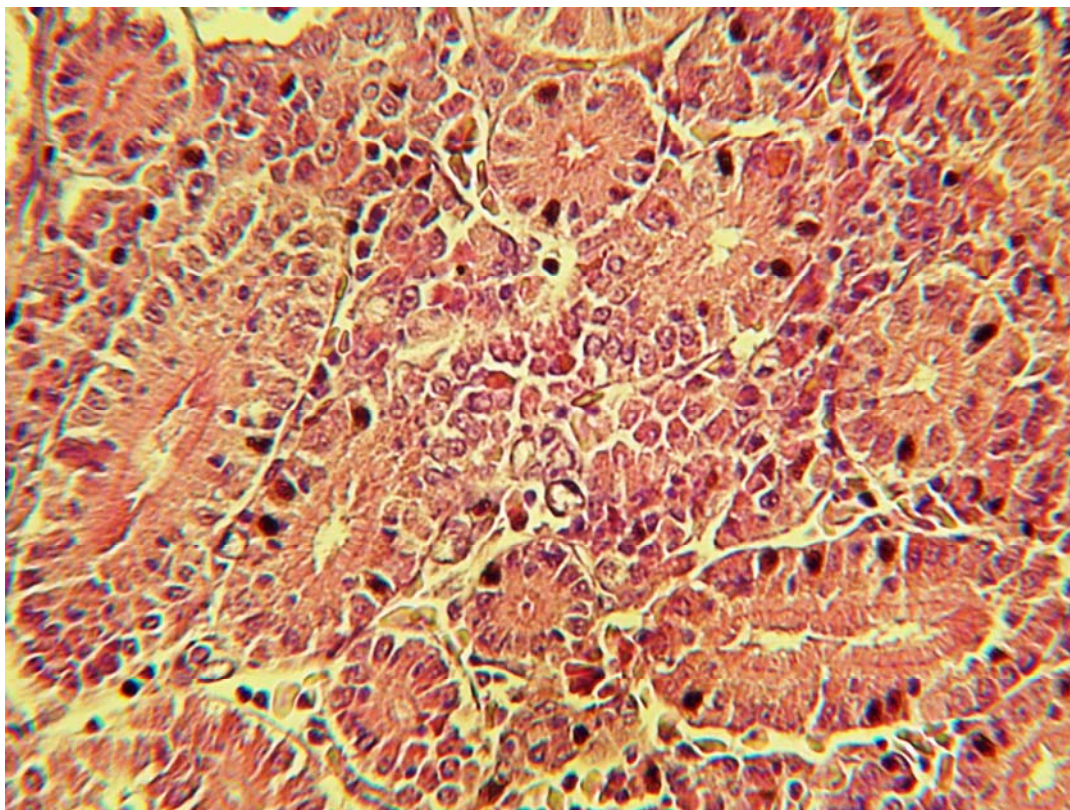


Figure 5. Pyknotic changes and/or deposition of hemosiderin in the epithelial cells of some tubules and macrophages. Kidney. HE, $\times 260$

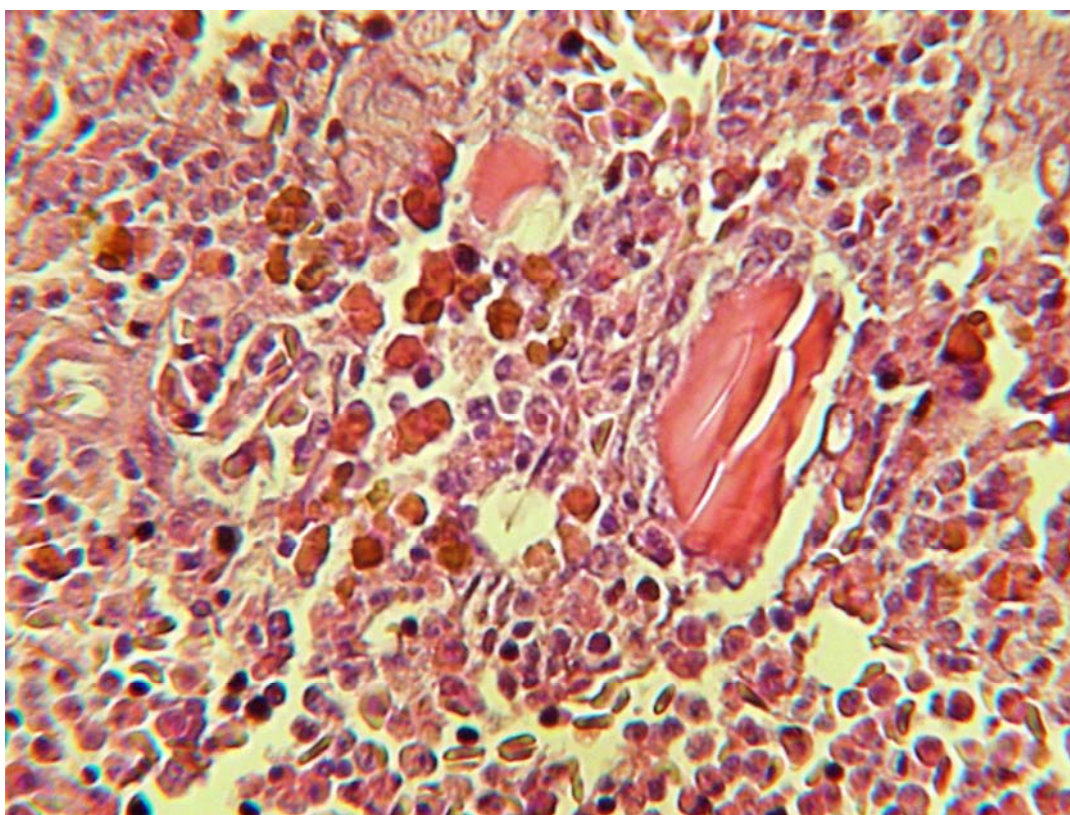


Figure 6. Hyaline casts in the lumens of some tubules and hemosiderin-laden macrophages in the hematopoietic tissues. Kidney. HE. $\times 260$

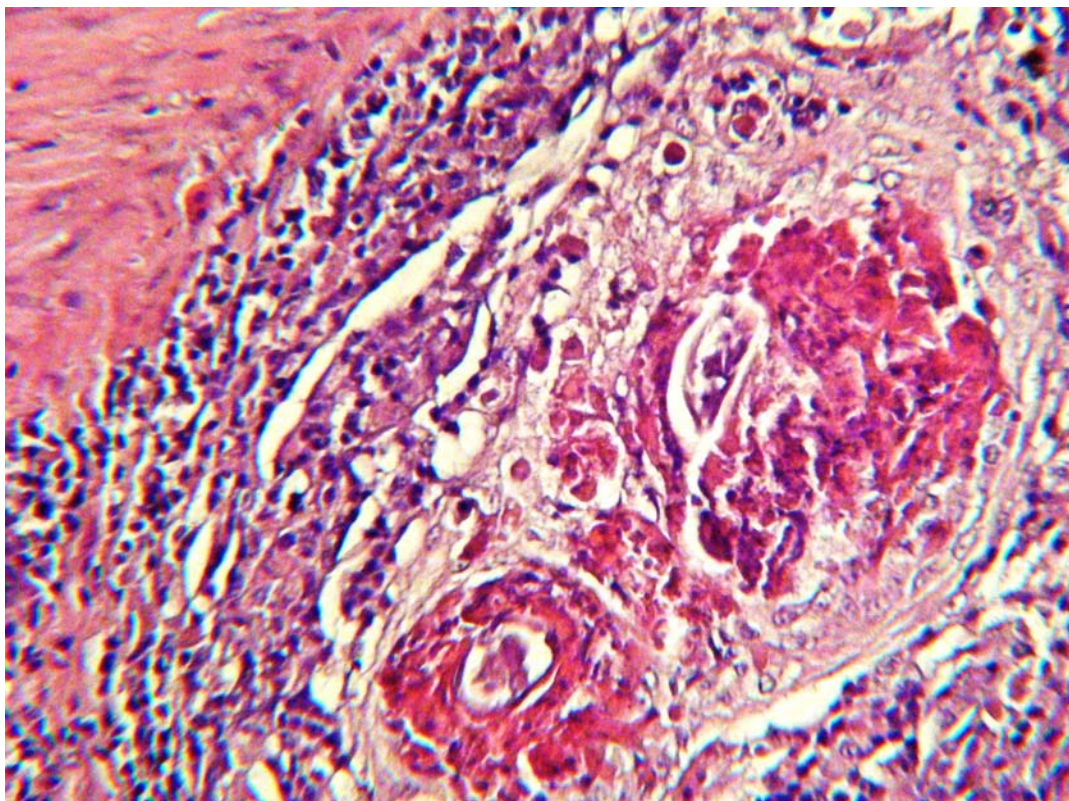


Figure 7. Necrotic foci with peripheral inflammatory cell infiltration in the tunica propria or lamina muscularis of intestinal mucosa. Intestine. HE. $\times 260$

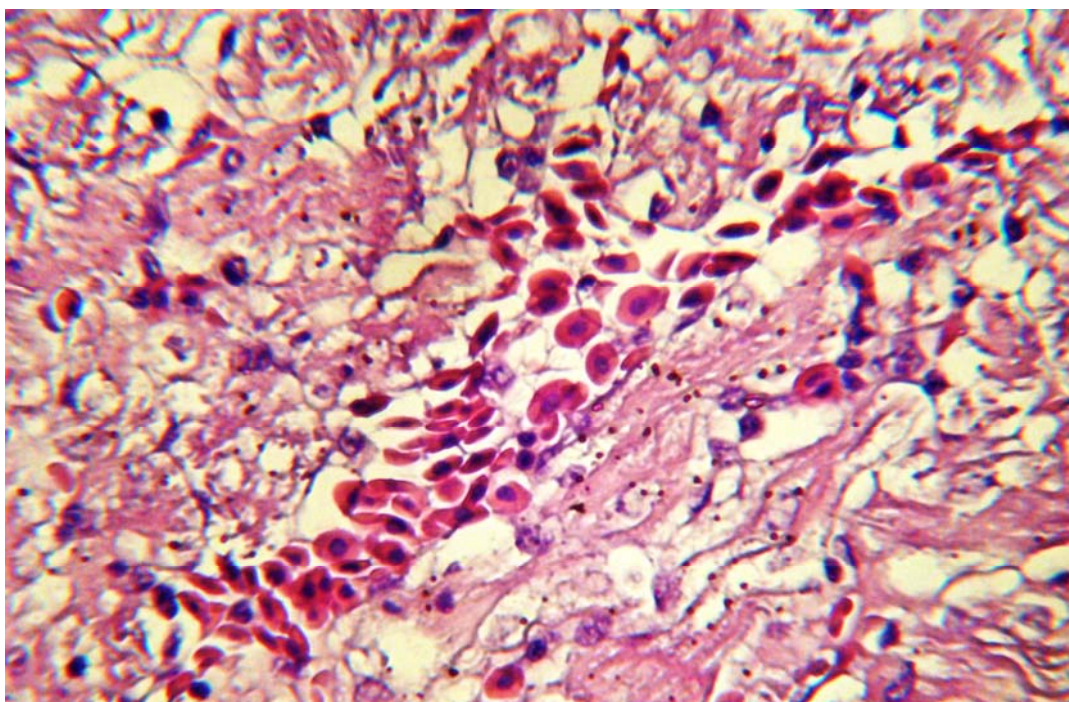


Figure 8. Small hemorrhages and slight granular degeneration or vacuolation in part of myofibrils. Heart. HE. $\times 300$

Similar study with Tilapia showed that experimental intramuscular infection with *Aeromonas hydrophila* at levels of 10^7 cfu/fish produced characteristic ulceration leading to open wounds, focal necrosis or vacuolation of hepatocytes, congestion of hepatic sinuses and haemorrhages in the liver, degenerative changes and necrosis of tubular epithelium of kidneys as well as degenerative changes in intestinal epithelium, erosion and sloughing of intestinal microvilli (Azad et al., 2001). The infection with higher levels of the same bacteria often provoked the death of some fishes (Azad et al., 2001).

Comparing the pathogenicity of the both isolated bacteria with the referent strain of *Aeromonas hydrophila* we can conclude that the intensity of pathological damages observed in the present study was a little higher in carps infected with *Aeromonas hydrophila* isolated from anaconda, followed by carps infected with referent strain of *Aeromonas hydrophila* and a less intensity of pathological damages was seen in carps infected with *Aeromonas hydrophila* isolated from a silver carp. In the fishes infected with the strain isolated from anaconda or the referent strain there were strong damages in blood vessels as hyperaemia and haemorrhages (mainly in kidneys and hearth) in addition to degenerative changes in various internal organs.

As a whole our experimental investigations support those made by some other authors (Yardimci and Aydin, 2011; Angka, 1990; Alagappan et al., 2009; Miyazaki and Kaige, 1985) in various kinds of fishes as Tilapia, Walking Catfish, Estuarine Cattfish, Crucian Carp, etc, infected intraperitoneally with *Aeromonas hydrophila* or those of spontaneous cases of this infection (Miyazaki and Jo, 1985). In mentioned above reports there were similar or even stronger degenerative or necrotic changes and haemorrhages in internal organs (liver, kidneys, hearth, spleen, intestine) as compared to our study, in addition to some haemorrhages or ulcers/erosions on the skin surface (Azad et al., 2001; Angka, 1990; Miyazaki and Jo, 1985; Miyazaki and Kaige, 1985), haemorrhages or ulcers/erosions around pectoral fins, tail and anus (Alagappan et al., 2009; Miyazaki and Jo, 1985), accumulation of red-coloured ascitic fluid (Miyazaki and Kaige, 1985), erosive cornea, separated retina, haemorrhages and necroses in the conjunctiva, exophthalmia (Rehulka, 2002; Miyazaki and Jo, 1985). Other authors reported about increased mortality and

more intensive pathological damages in Nile tilapia or Walking Catfish infected with *Aeromonas hydrophila* (Yambot and Inglis, 1994; Rodriguez et al., 1992; Angka, 1990), or in Crucian Carp (Miyazaki and Kaige, 1985) and Rainbow Trout (Rehulka, 2002) infected with the same bacterium.

Systemic infections in fishes with *Aeromonas hydrophila* were characterized by diffuse necrosis in several internal organs and the presence of melanin-containing macrophages in the blood (Ventura and Grizzle, 1988). The kidneys and liver are target organs in acute septicaemia which are apparently attacked by bacterial toxins and therefore lose their structural integrity (Afifi et al., 2000; Huizinga et al., 1979). The reason of degenerative changes and necrosis in the liver was reported to be associated with various endotoxins and extracellular products such as hemolysin, protease, elastase produced by *Aeromonas hydrophila* (Afifi et al., 2000; Kanai and Wakabayashi, 1984; Nieto et al., 1991; Angka, 1990; Rodriguez et al., 1992). The pronounced destructive changes in the skin and muscles followed by focal ulceration of the skin and vascular damages are usually attributed to hemolysin and protease activity of *Aeromonas hydrophila*, which possess also ability to adhere to cells (Azad et al., 2001; Wakabayashi et al., 1981; Kanai and Wakabayashi, 1984). The bacterial enzyme elastase could also contribute significantly to vascular damages (Wakabayashi et al., 1981) resulting in hemorrhages because blood vessels are mainly composed of elastic and collagenous fibers (Miyazaki and Kubota, 1977).

Huizinga et al. (1979) reported that focal haemorrhages and dermal lesions or ulcers were observed in chronic aeromonad infection, whereas the target organs in acute septicaemia were liver and kidneys. That could explain the mildness of the skin lesions and the pronounced damages in the liver and kidneys seen in our short duration follow up study. In addition, the intraperitoneal way of infection of fishes could contribute to intensive pathological changes in internal organs and less damages in the skin and muscles, because of ensuring a direct contact of this bacterium with visceral organs. On the other hand, stronger damages on the skin and muscles are usually reported in fishes infected via intramuscular injections (Yardimci and Aydin, 2011; Erer, 1981). However, the bacterial virulence in fishes intraperitoneally injected is always higher than in

fishes intramuscularly injected with this bacterium (Erer, 1981; Miyazaki and Kaige, 1985).

For increased amounts of hemosiderin-laden macrophages or epithelial cells in the liver, kidneys and spleen in *Aeromonas hydrophila* infection in fishes reported some other authors (Ventura and Grizzle, 1988; Miyazaki and Kaige, 1985). As a rule, the infections with strong β -hemolytic strains of *Aeromonas hydrophila* usually cause stronger deposition of hematoidin crystals and increase of hemosiderin-laden cells in various internal organs (Miyazaki and Kaige, 1985).

Similar degenerative changes, including hyaline droplet degeneration in tubular epithelium of kidneys in *Aeromonas hydrophila* infection in Crucian Carp were reported by some other authors (Miyazaki and Kaige, 1985). There are also some reports for focal interstitial hemorrhages, lymphocyte infiltration, appearance of hemosiderin-laden macrophages and aggregation of melanomacrophage centres in the renal interstitium seen in other fishes infected with the same pathogen (Erer, 1981; Azad et al., 2001).

Other authors (Huizinga et al., 1979) reported that no lesions were observed in heart and spleen in the acute cases of *Aeromonas hydrophila* infection in fishes and mainly diffuse tissue necrosis of liver and kidneys were present, which was also confirmed in the present study.

Although it is known that *Aeromonas hydrophila* has much notoriety as pathogen of fish it is important to mention that aeromonad bacteria are common inhabitant of aquatic environments and compose part of the normal intestinal or skin microflora of healthy fish (Lallier and Daigneault, 1984; Dooley et al., 1986; Yardimci and Aydin, 2011). That's why, the presence of these bacteria, by itself, in the intestines or skin of fishes, is not indicative of disease. Although this bacterium behaves as a secondary invader (Roberts, 1978) and the infection only occurs under various predisposing conditions, *Aeromonas hydrophila* is considered to be one of the most dangerous and widespread pathogens of freshwater fishes and the most important causative agent of the outbreaks of Bacterial hemorrhagic septicaemia in fishes (Austin B. and Austin D., 1993), known also as red pest or red disease (Hoshina, 1962).

According to some authors (Khalil and Mansour, 1997; Trust et al., 1974) various stressors as abrupt temperature change, handling, crowding, in-

adequate feed and oxygen are known to be the predisposing factors which contribute significantly to the infection of *Aeromonas hydrophila*, which is considered to be a real secondary infection in most of the fishes.

Aeromonas hydrophila is often associated with human disease (Hazen et al., 1978), which contributes further to the particular attention given to this bacterium. On the other hand, *Aeromonas hydrophila* is not generally considered to be a marine bacterium, but it could be found naturally in marine systems which interface with fresh water and therefore has a comparatively wide spreading. Having in mind the strong adherence of this bacterium to intestine and skin followed by invasion of the liver, spleen, muscle and gills of fishes (Horne and Baxendale, 1983; Kanno et al., 1989) in addition to its involving in gastrointestinal diseases and localized wound infection in humans, its recognition via some typical pathomorphological damages could additionally contribute to timely diagnosis of this disease.

Conclusions

This study clearly shows that typical histopathological alterations seen in the functional epithelium of liver and kidneys, followed by intestine and heart alterations and various haemorrhages in interstitial tissues of visceral organs, in addition to some target skin damages are good biomarkers for field assessment of that disease.

References

- Afifi, S.H., Al-Thobiati, S., Hazaa, M.S. (2000): Bacteriological and histopathological studies on *Aeromonas hydrophila* infection of Nile tilapia (*Oreochromis niloticus*) from fish farms in Saudi Arabia. *Assiut Veterinary Medical Journal*, 84: 195-205.
- Alagappan, K.M., Deivasigamani, B., Kumaran, S., Sakthivel, M. (2009): Histopathological alterations in Estuarine Catfish (*Arius maculatus*; Thunberg, 1792) due to *Aeromonas hydrophila* infection. *World Journal of Fish and Marine Sciences*, 1(3): 185-189.
- Alsaphar, S.A.A., Al-Faragi, J.K.H. (2012): Detection and study of the experimental infection of *Aeromonas* strain in the common carp (*Cyprinus carpio* L.), *The Iraqi Journal of Veterinary Medicine*, 36(2): 222– 230.
- Angka, S.L. (1990): The pathology of the walking catfish, *Clarias batrachus* (L.), infected

- intraperitoneally with *Aeromonas hydrophila*. *Asian Fisheries Science*, 3: 343-351.
- Austin, B. and Austin, D. (1993): Bacterial fish pathogens. In: Disease in "Farmed and Wild Fish", 2nd edition. Ellis Horwood, Chichester, United Kingdom, pp. 1-552.
- Azad, I.S., Rajendran, K.V., Rajan, J.J.S., Vijayan, K.K., Santiago T.C. (2001): Virulence and histopathology of *Aeromonas hydrophila* (Sah 93) in experimentally infected tilapia, *Oreochromis mossambicus* (L.). *Journal of Aquaculture in the Tropics*, 16(3): 265-275.
- Dooley, J.S.G., Lallier, R., Trust, T.J. (1986): Surface antigens of virulent strains of *Aeromonas hydrophila*. *Veterinary Immunology and Immunopathology*, 12: 339-344.
- Erer, H. (1981): The investigation of the pathologic findings of experimental *Aeromonas hydrophila* infection (Bacterial Haemorrhagic Septicaemia) in carp, PhD thesis, Ankara University.
- Hazen, T.C., Fliermans, C.B., Hirsch, R.P., Esch, G.W. (1978): Prevalence and distribution of *Aeromonas hydrophila* in the USA. *Applied and Environmental Microbiology*, 36: 731-738.
- Horne, M.T., Baxendale, A. (1983): The adhesion of *Vibrio anguillarum* to host tissues and its role in pathogenesis. *Journal of Fish Disease*, 6: 461-471.
- Hoshina, R. (1962): Studies on red disease of Japanese eel. *Journal of the Tokyo University of Fisheries*, 6(1): 1-104.
- Huizinga, H.W., Esch, G.W., Hazen, T.C. (1979): Histopathology of red-sore disease (*Aeromonas hydrophila*) in naturally and experimentally infected largemouth bass *Micropterus salmoides* (Lacépède). *Journal of Fish Disease*, 2: 263-277.
- Kanai, K., Wakabayashi, H. (1984): Purification and some properties of protease from *Aeromonas hydrophila*. *Bulletin of the Japanese Society for the Science of Fish*, 50(8): 1367-1374.
- Kanno, T., Nakai, T., Muroga, K. (1989). Mode of transmission of vibriosis among Ayu, *Plecoglossus altivelis*. *Journal of Aquatic Animal Health*, 1: 2-6.
- Khalil, A.H., Mansour, E.H. (1997): Toxicity of crude extracellular products of *Aeromonas hydrophila* in tilapia, *Tilapia nilotica*. *Letters in Applied Microbiology*, 25: 269-273.
- Lallier, R., Daigneault, P. (1984): Antigenic differentiation of pili from non-virulent and fish pathogenic strains of *Aeromonas hydrophila*. *Journal of Fish Diseases* 7: 509-572.
- Miyazaki, T., Kubota, S.S. (1977): Histological studies of tissue and organs of fish and the application to fish pathologies, I. Vascular system of Japanese eel (*Anguilla japonica*). *Bulletin of the Faculty of Fisheries Mie University*, 4: 81-82.
- Miyazaki, T., Jo, Y. (1985): A histopathological study of motile aeromonad disease in Ayu. *Fish Pathology*, 20(1): 55-59.
- Miyazaki, T., Kaige, N. (1985): A histopathological study on motile Aeromonad disease of Crucian carp. *Fish Pathology*, 21(3): 181-185.
- Nemetz, T.G., Shotts, E.B. (1993): Zoonotic diseases. In: Stoskopf, M.K. Saunders, W.B. (Eds.), *Fish Medicine*, Philadelphia, pp. 214-220.
- Nieto, T.P., Santos, Y., Rodriguez, L.A., Ellis, A.E. (1991): An extracellular acetyl choline esterase produced by *Aeromonas hydrophila* is a major lethal toxin for fish. *Microbial Pathogenesis*, 11: 101-110.
- Olivera, S.R., Souza, R.T.Y., Brasil, E.M., Andrade, J.I.A., Nuness, É.S.S., Ono, E.A., Afonso, E.G. (2011): LD50 of the bacteria *Aeromonas hydrophila* to matrinxã, *Brycon amazonicus*, *Acta Amazonica*, 41(2): 321 - 326
- Palumbo, S., Abeyta, C., Stelma, G., Wesley, I.W., Wei, Ch., Koberger, J.A., Franklin, Sh.K., Schoeder-Tucker, L., Murano, E.A. (2001): *Aeromonas*, *Acrobacter*, and *Plesiomonas*. In: Downes, F.P., Ito, K.A. (Eds.), *Compendium of methods for the microbiological examination of foods*. Fourth edition, American Public Health Association, Washington DC, pp. 283-300.
- Rehulka, J. (2002): *Aeromonas* Causes Severe Skin Lesions in Rainbow Trout (*Oncorhynchus mykiss*): *Clinical Pathology, Haematol-*

- ogy and Biochemistry. *Acta Veterinaria Brno*, 71: 351-360.
- Roberts, R.J. (1978): Fish Pathology. Billier Tindall, London, pp. 318.
- Rodriguez, L.A., Ellis, A.E., Nieto, T.P. (1992): Effects of acetylcholinesterase toxin of *Aeromonas hydrophila* on the central nervous system of fish. *Microbial Pathogenesis*, 14: 411-415.
- Thampuran, N., Surendran, P.K. (1995): Incidence of motile aeromonads in marine environment, fishes and processed fishery products. Proceedings of the National Symposium on Technological Advancements in Fisheries and its Impact on Rural Development. School of Industrial Fisheries, Cochin University of Science and Technology, 5-7 Dec 1995, pp. 352-358.
- Trust, T.J., Bull, M.L., Currie, B.R., Buckley, J.T. (1974): Obligate anaerobic bacteria in the gastrointestinal microflora of the grass carp (*Ctenopharyngodon idella*), goldfish (*Carassius auratus*), and rainbow trout (*Salmo gairdneri*). *Journal of the Fisheries Research Board of Canada*, 36: 1174-1179.
- Ventura, M.T., Grizzle, J.M. (1988): Lesions associated with natural and experimental infections of *Aeromonas hydrophila* in channel catfish *Ictalurus punctatus* (Rafinesque). *Journal of Fish Diseases*, 11: 397-407.
- Wakabayashi, H., Kanai, K., Hsu, I., Ecusa, S. (1981): Pathogenic activities of *Aeromonas hydrophila* biovar *hydrophila* (Chester) Popoff and Veron, 1976 to fishes. *Fish Pathology*, 15(3/4): 319-325.
- Yambot, A.V., Inglis, V. (1994): *Aeromonas hydrophila* isolated from Nile tilapia (*Oreochromis niloticus*) with "Eye Disease". International Symposium on Aquatic Animal Health. University of California, School of Veterinary Medicine, Davis, CA, pp. 103.
- Yardimci, B., Aydin, Y. (2011): Pathological findings of experimental *Aeromonas hydrophila* infection in Nile tilapia (*Oreochromis niloticus*). Ankara Üniversitesi Veteriner Fakültesi Dergisi. *Veterinary Journal of Ankara University*, 58: 47-54.